

A New Approach for Catheter Ablation of Atrial Fibrillation: Mapping of the Electrophysiologic Substrate

Koonlawee Nademanee, MD, FACC,* John McKenzie, MD,* Erol Kosar, MD,* Mark Schwab, MD,* Buncha Sunsaneewitayakul, MD,† Thaveekiat Vasavakul, MD,* Chotikorn Khunnawat, MD,* Tachapong Ngarmukos, MD‡

Inglewood, California; and Bangkok, Thailand

| | |
|--------------------|---|
| OBJECTIVES | We sought to test the hypothesis that complex fractionated electrograms (CFAEs) recorded during atrial fibrillation (AF) could be used as target sites for catheter ablation of AF. |
| BACKGROUND | Mapping of AF in humans has shown that areas of CFAEs correlate with areas of slowed conduction and pivot points of reentrant wavelets. We hypothesized that such areas of CFAEs could be identified in patients with AF and might serve as target sites for catheter ablation to maintain sinus rhythm. |
| METHODS | The study population included 121 patients (29 females; mean age, 63 years) with refractory AF (57 paroxysmal, 64 chronic). All patients underwent nonfluoroscopic electroanatomic mapping (CARTO) during AF. Using CARTO, the biatrial replica, displayed in a three-dimensional color-coded voltage map, was created during AF, and areas associated with CFAEs were identified. Radiofrequency ablation of the area with CFAEs was performed, aiming to eliminate CFAE and/or convert to sinus rhythm. |
| RESULTS | Complex fractionated atrial electrograms were found in seven of nine regions of both atria, but were mainly confined to the interatrial septum, pulmonary veins, roof of left atrium, and left posteroseptal mitral annulus and coronary sinus ostium. Ablations of the areas associated with CFAEs resulted in termination of AF without external cardioversion in 115 of the 121 patients (95%); 32 (28%) required concomitant ibutilide treatment. At the one-year follow-up, 110 (91%) patients were free of arrhythmia and symptoms, 92 after one ablation and 18 after two. |
| CONCLUSIONS | Areas with CFAEs represent a defined electrophysiologic substrate and are ideal target sites for ablations to eliminate AF and maintain normal sinus rhythm. (J Am Coll Cardiol 2004; 43:2044–53) © 2004 by the American College of Cardiology Foundation |

Moe et al. (1) described continuous propagation of multiple wavelets in the atria and wavelets as offspring of atrial reentry circuits as the mechanism by which atrial fibrillation (AF) may be perpetuated without continuous focal discharge. Allesie et al. (2) reported that there are two major underlying mechanisms of AF. One is random wavelet re-entry, and the other is leading circle reentry. An elegant study in humans by Hais-saguerre et al. (3) showed that ectopic impulses originating in the pulmonary veins could initiate AF, which could be eliminated by catheter ablation of these ectopic foci.

See page 2054

It is likely that, in humans, most AF is caused by more than one mechanism (2). During intraoperative mapping of AF, Konings et al. (4) observed that both random and leading circle reentry are present in patients with WPW

syndrome. These functional reentry circuits are difficult to map in detail in humans without performing open-heart surgery. Even with such surgery, many areas of the heart (e.g., the septum) may not be mapped simultaneously with the other sites. Nevertheless, Konings et al. (5) showed that the complex fractionated atrial electrogram (CFAE) observed during intraoperative mapping of human AF are found mostly in areas of slow conduction and/or at pivot points where the wavelets turn around at the end of the arcs of functional blocks. Thus, such areas of CFAEs during AF represent either continuous reentry of the fibrillation waves into the same area or overlap of different wavelets entering the same area at different times (4,5). Such complex electrical activity has a relatively short cycle length and heterogeneous temporal and spatial distribution in humans (6,7). We hypothesized that if the areas of CFAEs could be identified and associated with the atrial anatomy, it should then be possible to locate the areas where the AF wavelets reenter. If such areas were to be selectively eliminated by catheter ablation, wavelet re-entry should stop, thereby preventing perpetuation of AF.

We, therefore, conducted the following study to determine if CFAEs can identify the regions where AF is

From the *Pacific Rim Electrophysiology Research Institute, Inglewood, California; †Chulalongkorn University, Bangkok, Thailand; and ‡Ramathibodi Hospital, Mahidol University, Bangkok, Thailand.

Manuscript received September 23, 2003; revised manuscript received December 9, 2003, accepted December 15, 2003.

Abbreviations and Acronyms

| | |
|-------|--|
| AF | = atrial fibrillation |
| CAF | = chronic atrial fibrillation |
| CARTO | = electroanatomic mapping |
| CFAEs | = complex fractionated atrial electrograms |
| CS | = coronary sinus |
| LIPV | = left inferior pulmonary vein |
| LSPV | = left superior pulmonary vein |
| PAF | = paroxysmal atrial fibrillation |
| RIPV | = right inferior pulmonary vein |
| RSPV | = right superior pulmonary vein |

perpetuated and if CFAEs can be used to target such sites for catheter ablation of AF.

METHODS

Study population. We studied 121 patients (92 men, 29 women; mean age, 63 ± 12), 64 of whom had chronic AF (CAF) (26 had persistent AF, 38 had permanent AF) and 57 paroxysmal AF (PAF)—PAF was self-terminating within seven days of the onset; persistent AF was not self-terminating within seven days or was terminated by either electrical or pharmacologic conversion, and permanent AF could not be terminated by cardioversion or was not attempted. Most of these patients had a long history of AF (4 ± 3.3 years) and had failed at least two previous antiarrhythmic drugs (mean, 2.4 ± 1.3). Seventy-nine patients had heart diseases: 42 had coronary artery disease, 17 cardiomyopathy, 14 valvular heart diseases, and 6 congenital disease. The mean left atrial dimension was 42 ± 6 mm.

Electrophysiologic study and electroanatomic mapping (CARTO). After giving informed written consent approved by our institutional review board, patients underwent electrophysiologic studies under conscious sedation. For recording and stimulation, multipolar electrode catheters were positioned in the coronary sinus (CS) and/or right atrium. Atrial fibrillation was induced in the patients who had PAF but who were in sinus rhythm during the time of study. The patients with premature atrial contractions were given isoproterenol infusion; if sustained AF was not provoked, then rapid atrial pacing was performed, with or without isoproterenol infusion. For patients with infrequent premature atrial contractions, the same pacing protocol was performed with or without isoproterenol. Once AF was sustained for over 5 min, the patients underwent nonfluoroscopic electroanatomic mapping (8,9), as did the patients with CAF. The CS or right atrial appendage recording was used for electrical reference during CARTO mapping. Intracardiac recordings were simultaneously recorded with the CARTO and a computerized multichannel recording system (EP Med Systems Inc., Mt. Arlington, New Jersey). Tachycardia cycle lengths were monitored and recorded from both the reference and the mapping catheter.

The CARTO system created biatrial replicas as a three-

dimensional map. The CARTO enabled navigation within the cardiac chamber and combined three-dimensional endocardial anatomy with electrical activation wave fronts or voltage. The physician could thereby locate, tag, and later revisit relevant sites. Heparin (5,000 U bolus followed by 1,500 U every h) was used for anticoagulation.

During AF, the local activation time of the arrhythmia was of no value in guiding activation sequence mapping because we did not simultaneously map multiple sites in both atria. However, CARTO provided an invaluable voltage map and enabled the operator to associate areas of CFAEs with the anatomy of both atria. We used bipolar recording filtered at 30 to 500 Hz and defined low voltage as being ≤ 0.15 mV. We define CFAEs as follows: 1) atrial electrograms that have fractionated electrograms composed of two deflections or more, and/or perturbation of the baseline with continuous deflection of a prolonged activation complex over a 10-s recording period (Fig. 1A); 2) atrial electrograms with a very short cycle length (≤ 120 ms) (Fig. 1B) averaged over a 10-s recording period. The CFAEs were tagged and associated with the atrial anatomy created by CARTO, thereby serving as target sites for ablation.

Radiofrequency ablation. With a three-dimensional anatomic guide, the areas with CFAEs could be located and ablated. Radiofrequency energy was delivered between the distal electrode of the locatable mapping catheter and a large patch electrode placed on the patient's back. Radiofrequency applications were delivered with the maximal temperature of 55°C to 60°C at the catheter tip; only a standard 4-mm tip catheter was used in this study.

End points and data analysis. The primary end points during radiofrequency ablation of AF were: either complete elimination of the areas with CFAEs or conversion of AF to normal sinus rhythm for both CAF and PAF patients; 2) noninducible AF for PAF patients. When the areas with CFAEs were completely eliminated but the arrhythmias continued as organized atrial flutter or atrial tachycardia, the atrial tachyarrhythmias were mapped and ablated (occasionally in conjunction with ibutilide, 1 mg for 10 min) to revert the arrhythmias to sinus rhythm. If the arrhythmias were not successfully terminated, external cardioversion was performed.

The patients were then followed in the arrhythmia clinic every three months. For the follow-up and documentation of arrhythmia recurrences, Holter and event monitor recordings were used in conjunction with routine electrocardiogram.

RESULTS

The mean procedure time was 3.1 ± 0.85 h, and the fluoroscopy time was 14.7 ± 4.8 min. The number of radiofrequency applications delivered was 64 ± 36 (range, 7 to 168) applications. During the ablative procedure, all 57 PAF patients went into sinus rhythm and rendered AF

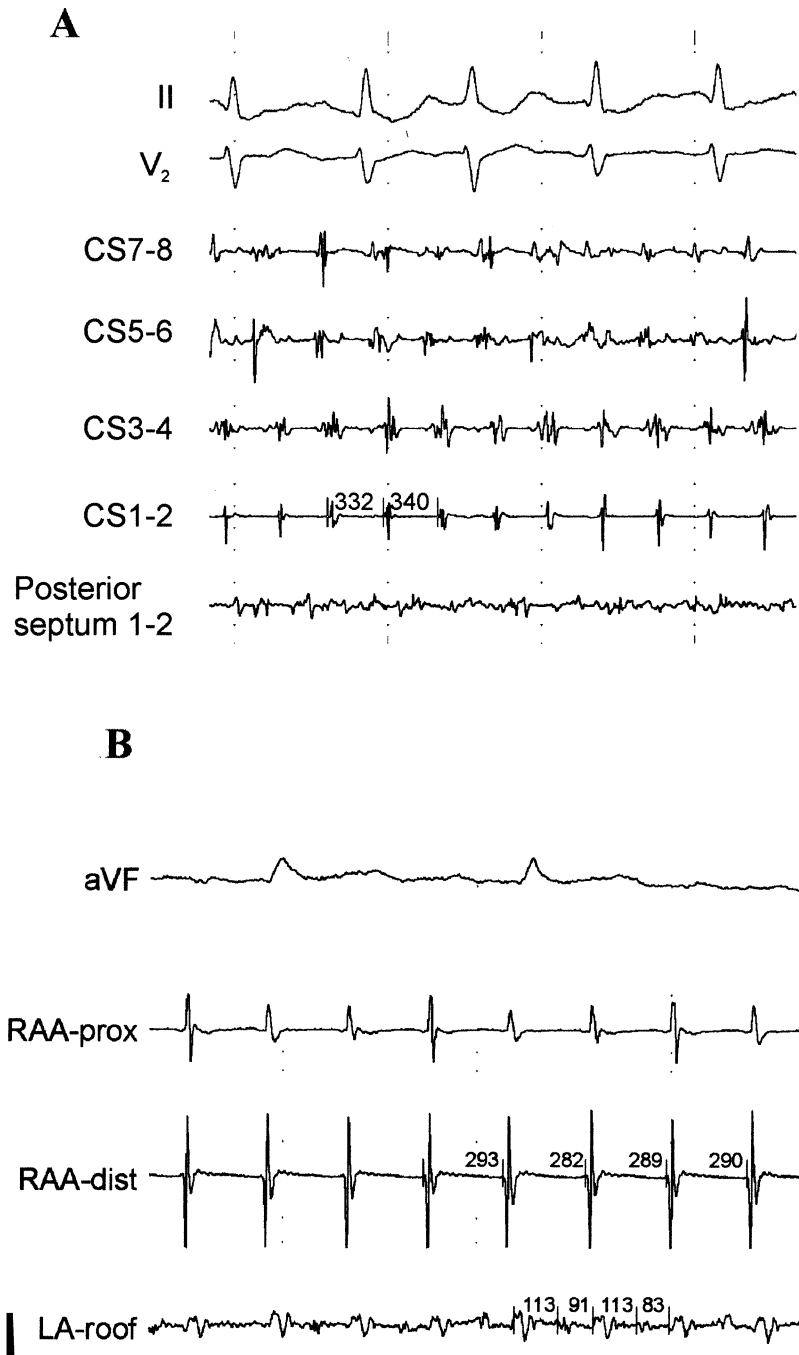


Figure 1. Examples of complex fractionated atrial electrograms (CFAE): (A) Shows fractionated electrograms with continuous prolonged activation complex over the posterior septal areas. (B) Shows another type of CFAE at the left atrium (LA)-roof where electrograms with a very short cycle length, compared with the rest of the atria, were recorded. CS = coronary sinus.

noninducible—eight (14%) required concomitant ibutilide treatment. Fifty-eight of the 64 CAF patients (91%) had AF converted to sinus rhythm during ablation—18 (28%) required concomitant ibutilide treatment. The remaining six CAF patients (9%) needed cardioversion with ibutilide to attain sinus rhythm.

Evidence that CFAEs represent substrate areas that perpetuate AF. Figure 2 shows the intracardiac recording from a patient who had permanent AF and under-

went atrioventricular nodal ablation followed by implantation of a permanent pacemaker three years previously. Intracardiac atrial electrograms displayed CFAEs, which were located exclusively in the septum; the rest of the atria showed discrete organized electrograms (Fig. 2A). The fibrillation cycle length along both sides of the septum was ≤ 120 ms, in contrast with the 235 to 280 ms cycle length at the left and right atrial appendages and lateral wall of both atria. The voltage map (Figs. 2B and

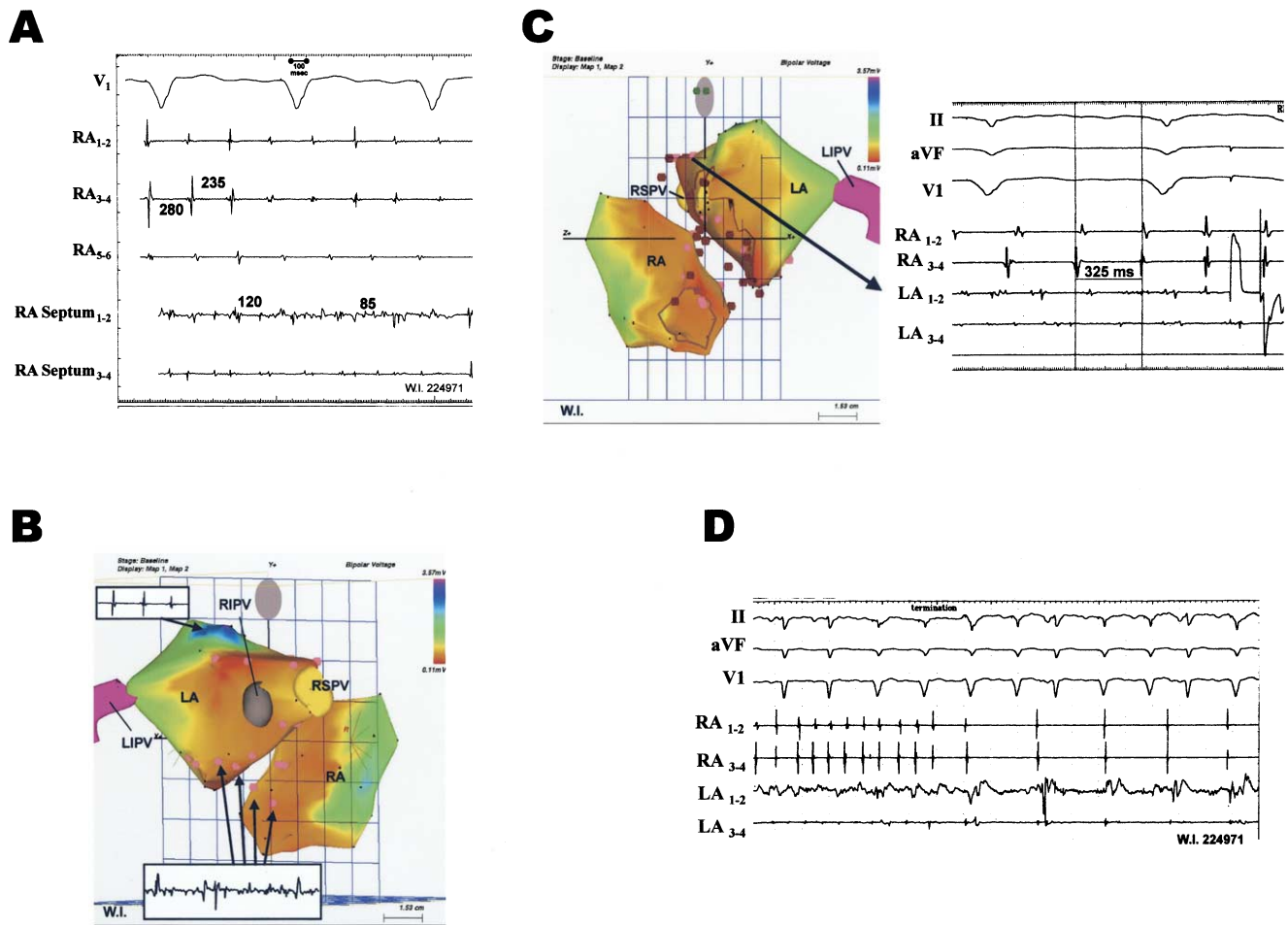


Figure 2. An example of electroanatomic mapping (CARTO) of a patient with permanent atrial fibrillation. **(A)** Complex fractionated atrial electrograms (CFAE) are seen over the right atrial (RA) septum₁₋₂ and RA septum₃₋₄; in contrast, the lateral wall of the RA shows discrete organized single-potential atrial electrograms (RA₁₋₂ and RA₃₋₄). **(B)** Electroanatomic mapping voltage map presents the posteroanterior view. **Pink dots** are areas of CFAEs along both sides of the atrial septum. **(C)** Left anterior oblique view of the CARTO voltage map displaying ablation points (**red dots**). Left atrial (LA)₁₋₂ and LA₃₋₄ are the intracardiac recordings from the superior-anterior aspect of the interatrial septum (**arrow**). **(D)** Termination of the tachycardia during the ablation. LIPV = left inferior pulmonary vein; RIPV = right inferior pulmonary vein; RSPV = right superior pulmonary vein.

2C) confirmed that both the low voltage areas and the CFAEs were confined almost exclusively to both sides of the septum. After radiofrequency ablation applications along both sides of the septum, the tachycardia cycle length increased to 325 ms before termination (Figs. 2C and 2D). The patient continued to be arrhythmia free two years after the ablation.

After radiofrequency applications, most atrial electrograms either disappeared or reduced drastically in amplitude resulting in complete elimination of CFAEs—often associated with organization of atrial electrograms in the areas adjacent to the ablated ones. The elimination of CFAEs always uniformly increased tachycardia cycle lengths before AF termination, even though the cycle lengths were measured from the electrical reference from the area remote from the ablation sites. The overall tachycardia cycle length increased from 172 ± 26 ms at baseline to 237 ± 42 ms ($p < 0.05$).

Regional distribution of CFAEs. For the purpose of characterizing human AF using a biatrial CARTO map, we divided the right and left atria into nine areas (Fig. 3). Electroanatomic mapping not only enabled us to navigate freely in both atria, but also allowed us to revisit the areas of interest where CFAEs were found earlier. The CFAEs were distributed differently in the nine regions; they were, however, not migratory as confirmed by revisiting the areas before the ablation was initiated. Our mapping demonstrated that AF is heterogeneous and can be divided into three types based on the regional distribution of the CFAEs (Table 1):

Type I: The CFAEs were localized in only one area, and the rest of the atria displayed discretely organized atrial electrograms. Typically, the cycle length in the area with CFAEs was much shorter than the cycle length in the rest of the atria (Fig. 4). Radiofrequency ablation applications applied to

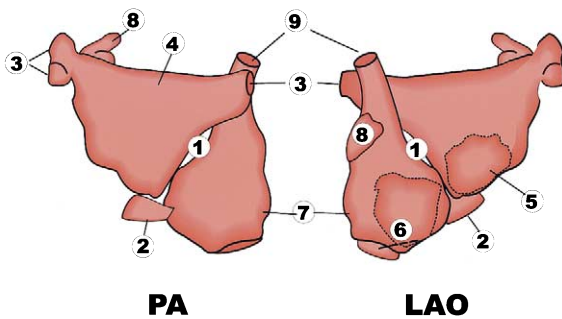


Figure 3. Based on electroanatomic mapping (CARTO), the biatrial replica could be divided into the nine separate areas: 1) septum including the Bachmann bundle; 2) left posteroseptal mitral annulus and coronary sinus ostium; 3) pulmonary veins; 4) roof of the left atrium; 5) mitral annulus; 6) cavotricuspid isthmus; 7) crista terminalis; 8) right and left atrial appendages; and 9) superior vena cava-right atrial junction. LAO = left anterior oblique; PA = posterior anterior.

these areas resulted in the elimination of the CFAEs, with termination of the AF. Table 1 summarizes the regional distribution of our 23 type I—patients (16 with PAF and 7 with CAF) had the following type I distribution of CFAEs:

- Type II: The CFAEs were localized in two areas, and ablations had to be performed in both these areas to terminate AF. We classified pulmonary veins as one area regardless of how many veins were involved in the AF. Fifty-three patients (22 with CAF and 21 with PAF) had type II CFAEs (Table 1).
- Type III: The CFAEs were distributed in three or more areas. Figure 5 shows a voltage map displayed along with intracardiac electrograms. Multiple cardioversions (with amiodarone and ibutilide)

had been unsuccessful. The CFAEs were confined to the posterior wall, pulmonary veins, septum, and mitral annulus. After ablation along these areas, AF converted to atrial tachycardia. The atrial electrograms became organized, and continued application of radiofrequency along the posteroseptal area converted the tachycardia to sinus rhythm.

Fifty-five patients (35 CAF and 20 PAF) displayed CFAEs ≥ 3 areas in both atria. The regional distribution of the CFAE areas in these type III patients are shown in Table 1. The interatrial septum was the most common site for CFAEs in our patient population; other common sites were the pulmonary veins, roof of left atrium, and proximal CS. None of our patients had CFAEs in the appendages.

Atrial tachyarrhythmias after initial AF ablation: evidence that atria could no longer fibrillate. Although recurrent atrial tachyarrhythmias were common after the first session of ablation (experienced by 62 patients), the majority of the arrhythmias was not AF. The recurrent atrial tachyarrhythmias were paroxysmal in 27 patients and persistent in 35. Approximately three-fourths of the atrial arrhythmias consisted of atrial flutter and atrial tachycardia (n = 44; 71%) and one-fourth of AF (n = 18; 29%). Of the 62 patients with early recurrent atrial arrhythmias, 33 became arrhythmia free and symptoms free eight weeks after the initial ablation. The 29 patients who continued to have atrial tachyarrhythmias eight weeks after the initial ablations underwent a second ablation for the following arrhythmias: 5 had atypical left atrial flutter (4 in the

Table 1. Classification and Regional Differences of CFAE Distributions

| AF Classification | Number of Patients (Types) | Number of Patients at Various Location of CFAE Distribution |
|---|----------------------------|---|
| Type I AF: CFAEs localize in only one area | 23 (16 PAF and 7 CAF) | 10 pulmonary veins (4 RSPV; 3 LSPV; 1 LIPV and 2 both RSPV and LSPV) 8 interatrial septum 4 proximal CS 1 inferolateral aspect of the right atrium (Fig. 4) |
| Types II AF: CFAEs localize in two areas | 43 (21 PAF and 22 CAF) | 19 pulmonary veins and septum 9 septum and proximal CS 4 pulmonary veins and left posteroseptal mitral annulus 3 pulmonary vein and cavotricuspid isthmus 5 septum and mitral annulus 3 septum and the roof of the left atrium |
| Type III AF: CFAEs localize in ≥ 3 areas | 55 (20 PAF and 35 CAF) | 46 interatrial septum (83%) 37 pulmonary veins (67%) 34 left atrial roof (61%) 32 proximal CS and its os (59%) 13 mitral annulus (24%) 17 cavotricuspid isthmus (31%) 4 inferolateral aspect of the right atrium (7%) 2 SVC and right atrial junction (4%) |

AF = atrial fibrillation; CAF = chronic atrial fibrillation; CFAE = complex fractionated atrial electrogram; CS = coronary sinus; LIPV = left inferior pulmonary vein; LSPV = left superior pulmonary vein; PAF = paroxysmal atrial fibrillation; RSPV = right superior pulmonary vein; SVC = superior vena cava.

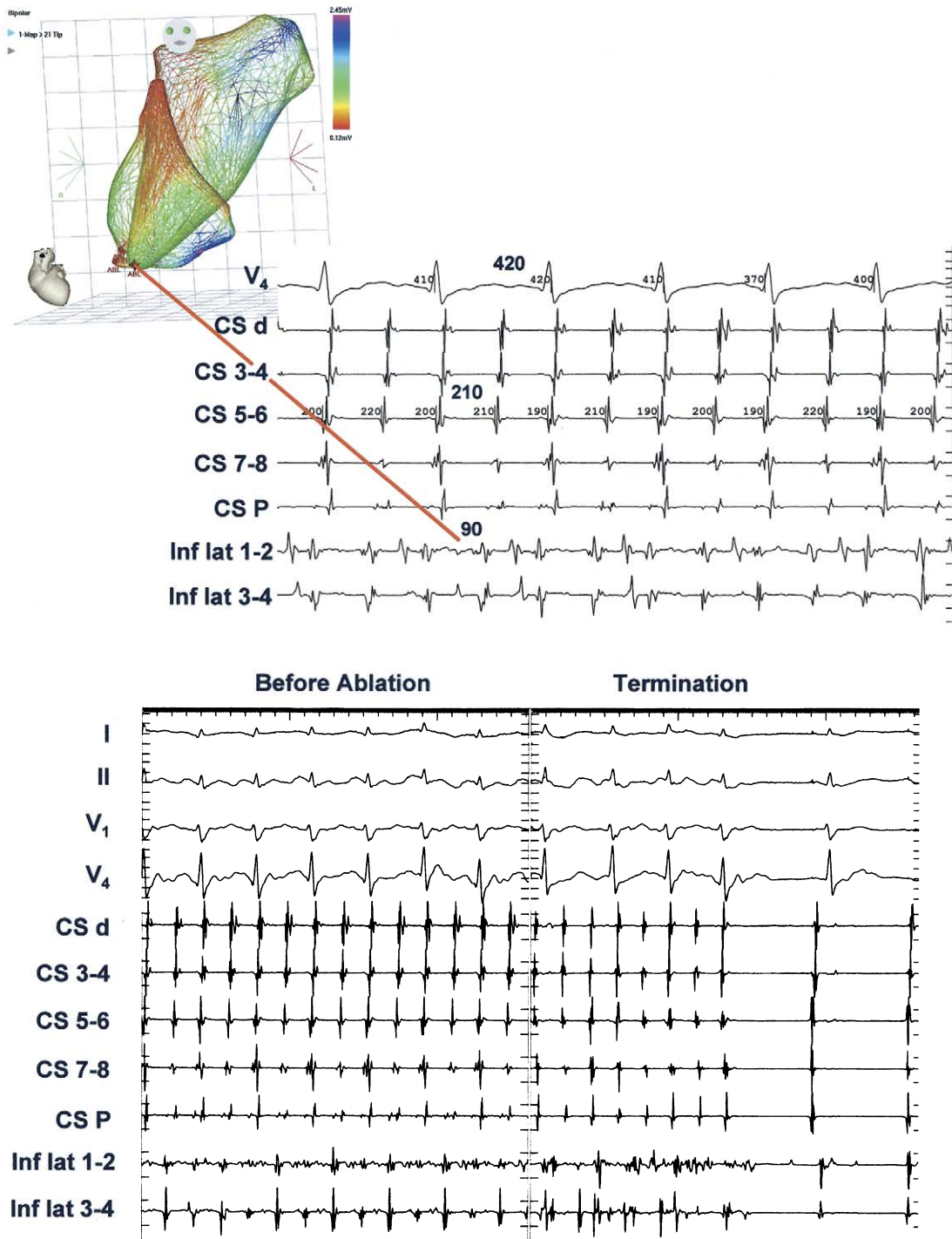


Figure 4. An example of type 1 atrial fibrillation (AF). This patient had symptomatic paroxysmal AF and had failed multiple drugs. The **top panel** shows the biatrial map (mesh presentation) in the anterior posterior view. The **arrow** points to the electrogram recorded from the inferolateral (inf lat) aspect of the right atrium. Note that the cycle length of the complex fractionated atrial electrograms in this area was quite short, only 90 ms. Radiofrequency ablation applications at this site terminated AF (**lower panel**) and rendered it noninducible. CS = coronary sinus.

interatrial septum and one in the roof of the left atrium), 10 had atrial flutter dependent on the cavotricuspid isthmus, 5 had atrial tachycardia (2 at the left superior pulmonary vein and 3 at the CS ostium), and 9 had AF.

Figure 6 shows examples of recurrent atypical atrial flutter obtained from patients represented in Figure 5 who had

become arrhythmia free for a few months before this atrial flutter occurred. Note that the atria could no longer fibrillate. The CARTO map shows the reentrant circuit in the posterior superior left atrium. Ablation at this site resulted in an increase in cycle length from 219 ms to 250 ms before tachycardia termination. Each of the 10 patients who devel-

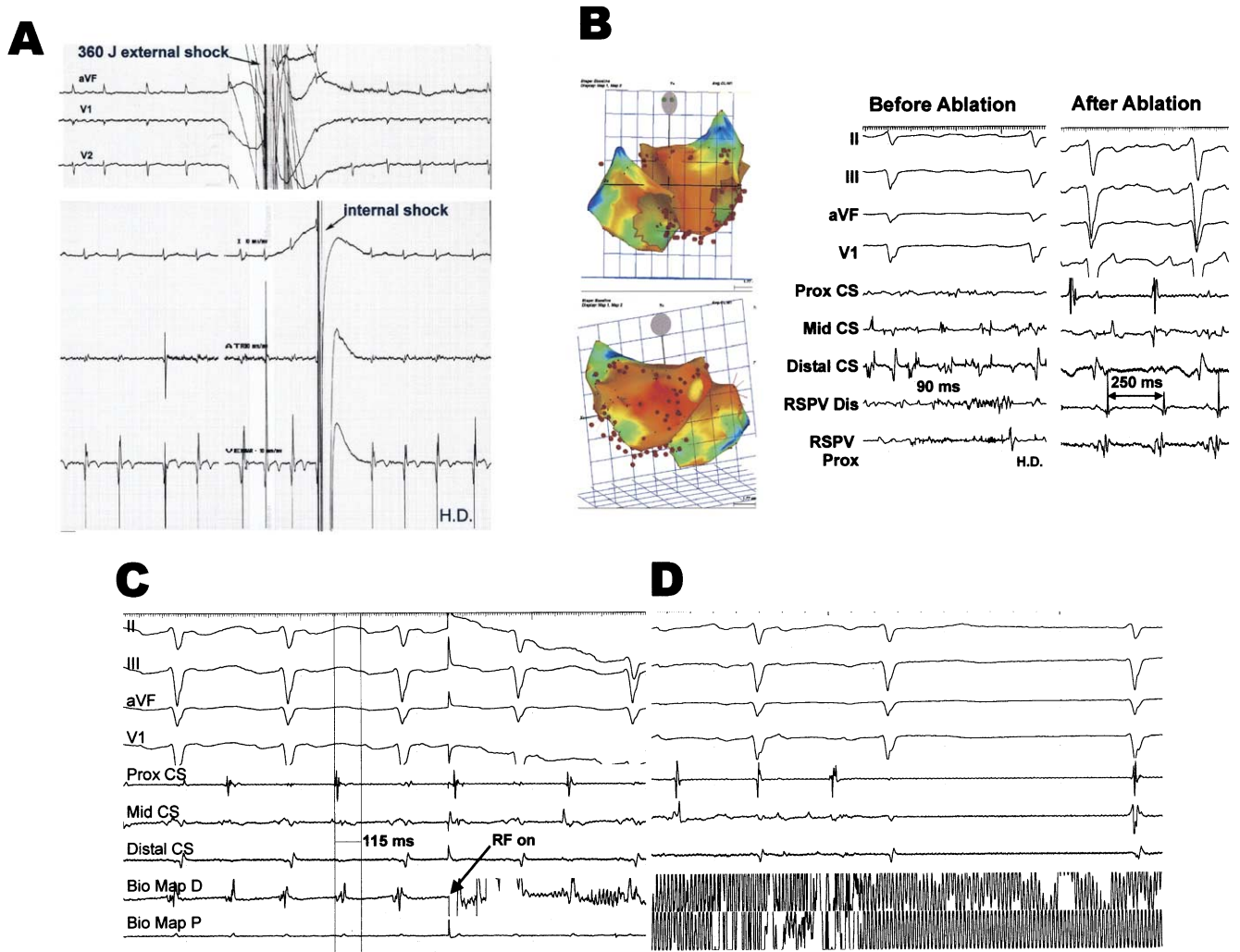


Figure 5. (A) Shows failure of external (top panel) and internal (lower panel) cardioversion to convert atrial fibrillation (AF) in patients with chronic permanent AF. (B) Voltage mapping with intracardiac recordings before and after ablations. The color range depicts red as the lowest voltage and blue and magenta as the highest voltage. The distribution of complex fractionated atrial electrograms was confined largely on the posterior wall of the left atrium, mitral annulus, and septum. (C) Shows the electrograms recorded from the mapping catheters at the left posteroseptal areas. Note that there are conduction blocks between these areas and the distal (Dis) coronary sinus (CS). The atrial activation at this site was 115 ms earlier than the P wave, and radiofrequency (RF) application here terminated the tachycardia (D). Biomap D = distal electrodes; Biomap P = proximal electrodes; prox = proximal; RSPV = right superior pulmonary vein.

oped isthmus atrial flutter had a successful ablation of the cavotricuspid isthmus resulting in elimination of recurrent arrhythmias. Figure 7 shows examples of ablation maps from four patients whose initial ablations were successful in eliminating AF but who developed recurrent cavotricuspid isthmus-dependent atrial flutter. Note that the initial ablations were not performed in the right atrium, which suggests that the recurrent atrial flutter was not related to the previous ablations but rather to a different arrhythmic mechanism.

Long-term outcomes. At the one-year follow-up, 92 of the 121 patients (76%) had only one ablative session and were free of arrhythmia; 47 were PAF (2 required amiodarone therapy), and 45 were CAF (3 required amiodarone and 2 sotalol). Ten PAF and 19 CAF patients required the second ablation: 7 PAF (one required amiodarone) and 11 CAF patients (two required amiodarone) became arrhythmia free. However, the remaining 11 patients (8 with CAF,

3 with PAF) continued to have recurrent atrial tachyarrhythmias; 4 of these patients required amiodarone, and 7 were treated with an atrial defibrillator. Overall, 110 patients (91%) were free of arrhythmia and symptoms without any late complications.

Procedure-related complications. Six patients experienced major complications. One patient had a cerebrovascular accident 24 h after the ablation. Two patients had cardiac tamponade; one had a complete atrioventricular block, and one had transient severe pulmonary edema. One patient developed a femoral arterial atrioventricular fistula, which necessitated surgical repair.

DISCUSSION

Our study presents a new way of mapping AF using CARTO. Our mapping data provide evidence for the

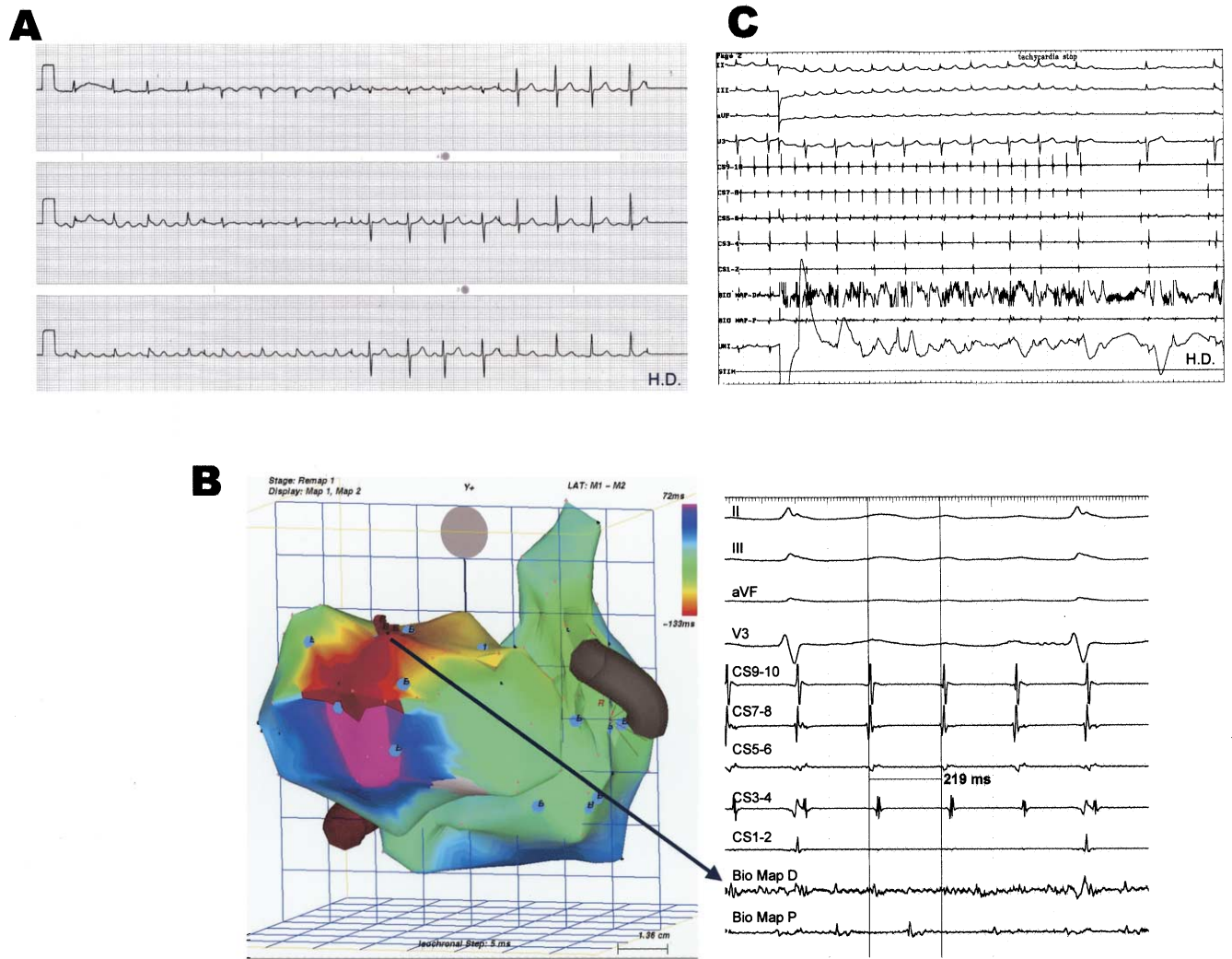


Figure 6. (A) Electrocardiogram showing recurrent atrial flutter of the same patient from Figure 6. (B) The map of the activation wave front during tachycardia; the color range depicts red as the earliest activation and magenta as the latest. The arrow points to the electrogram of the mapping electrodes at the left atrial roof where complex fractionated atrial electrograms with mid-diastolic potentials were recorded. Radiofrequency application at this site terminated the tachycardia (C). Biomap D = distal electrodes; Biomap P = proximal electrodes; CS = coronary sinus.

hypothesis that CFAE areas are critical sites for AF perpetuation and can serve as target sites for AF ablation. Once CFAEs were eliminated by ablation, AF could no longer be sustained in the majority of our patients. The tachycardia cycle length increased, and electrograms became more organized before termination of AF. This observation suggests that the random reentry paths were altered or eliminated so that the fibrillation wavelets could no longer reenter the ablated areas. This may be due to termination of the rhythm at the dead ends or circling of the wavelets around the ablated areas resulting in a more organized rhythm of a new macroreentrant circuit with a relatively longer cycle length. Atrial fibrillation was thereby converted to atrial tachycardia or flutter, the random reentry changed to a single macroreentrant circuit, a focal reentry, or a focal discharge.

Indeed, the atrial tachyarrhythmias that occurred after ablation may have been multifactorial. It is possible that the

ablation procedure itself caused the arrhythmias, as is commonly seen after the Maze surgical procedure (10) because of electrophysiologic changes that occur during the healing process and disappear once healing is complete (10). Further evidence for this theory was provided by the fact that many of the atrial arrhythmias that occurred in our patients after ablation ended eight weeks after the ablation.

Another possibility is that some of these arrhythmias were the primary arrhythmias that induced AF via fibrillatory conduction (11,12). Once the atria could no longer fibrillate after the ablations because the substrates for AF were eliminated, the primary arrhythmia manifested itself. Many of our patients who had cavotricuspid isthmus-dependent atrial flutter as the recurrent arrhythmia did not have this area ablated at the initial session, which supports this supposition. However, five patients with atypical atrial flutter had the reentrant circuits clearly defined in the areas where RF applications were performed: four had the re-

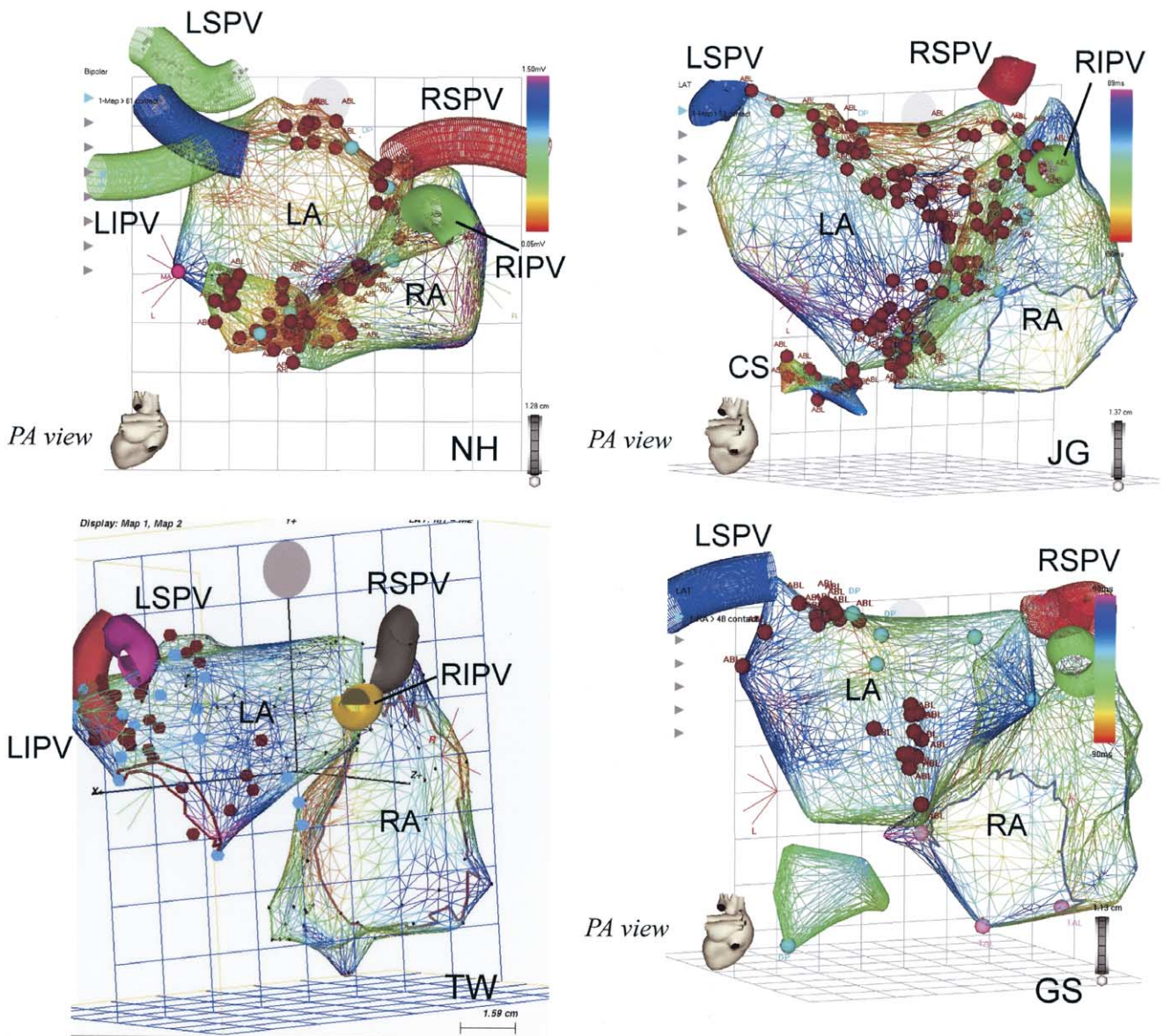


Figure 7. Posteroanterior (PA) views of four maps from four patients: N. H. and T. W. (**left**) were patients with paroxysmal atrial fibrillation (AF), and J. G. and G. S. (**right**) were patients with chronic AF. Ablations performed during AF at various areas of the left atrium (**red dots**) resulted in arrhythmia termination. CS = coronary sinus; LA = left atrium; LIPV = left inferior pulmonary vein; LSPV = left superior pulmonary vein; RA = right atrium; RIPV = right inferior pulmonary vein; RSPV = right superior pulmonary vein.

entrant circuits in the septum and one in the roof of the left atrium (Fig. 7). These patients most likely developed ablation-related macroreentrant tachycardia.

One possible shortcoming with the above mapping technique is that the atria were not simultaneously mapped with multiple electrodes. Nevertheless, one of our most intriguing findings was that the distribution and location of CFAEs remained relatively constant. This observation suggests that the electrical activities causing CFAEs by conduction disturbances during AF have a propensity to localize in the same areas and do not meander. Because the CARTO system enables one to revisit these areas of interest, we were able to mark the areas having CFAEs,

which then served as stationary targets for precise positioning of the ablation catheter (8,9). Nevertheless, one must reconcile the difference between the above finding and the earlier observation that the underlying mechanism for AF is random reentry and that the reentrant wavelets are expected to meander; in turn, the CFAEs should be fleeting. Possible explanations are as follows: 1) a linking phenomenon, previously described by Gerstenfeld *et al.* (7), maintains the direction of wavelet propagation during AF; 2) the previous mappings were done almost exclusively in patients with WPW syndrome, whereas our patient population had a long standing history of AF; and 3) mapping by previous investigators used the epicardial technique and was mostly

located over the lateral wall. We, however, mapped the entire atria from both sides including the septum, pulmonary veins, and CS; these areas are not amenable to epicardial mapping.

In any event, our findings confirm those of Jaïs *et al.* (6) that regional disparities of endocardial atrial activation exist in AF and that CFAEs have the proclivity to localize in the same areas. More importantly, our study also confirms their observation that the atrial septum is the most common site for CFAEs. Similarly, our data support the finding of Tondo *et al.* (13) that demonstrated that the midatrial septum is an important target site for AF perpetuation in the canine model in the pacing-induced AF in the normal dog heart (13). Recently, Quan *et al.* (14) showed that electrical stimulation of cardiac ganglia near the pulmonary vein orifices significantly shortened the atrial refractoriness close to the site of the stimulation and that the effects diminished at the distance >2 cm away from this site (14); this raises the possibility that neurotransmitter release (i.e., acetylcholine at preganglionic and/or postganglionic terminal) may contribute to the genesis of CFAEs and may play a role in the differences of CFAEs regional distribution in the atria during AF. In any event, CFAEs were rarely observed in the atrial appendage of either side, suggesting that the trabeculated area of the atrial appendage is rarely a part of the random reentry that sustains AF. This supposition is strengthened by the fact that even though we performed no ablation in either the right or left atrial appendage, AF was still terminated and was not inducible afterwards.

The immediate success rate with our approach was very high (95%), as determined by termination of arrhythmia during the ablations, while the complication rate was quite low. The immediate success was also translated into excellent clinical outcomes.

What is the difference between our approach and those used in pulmonary vein isolation? The latter is an ablative technique that aims to remove the triggering foci (3,15,16), while our technique aims to remove the substrate for AF. Our study is not designed to compare the efficacy rate between the two techniques. Our data, however, indicate that pulmonary veins are the key areas, after the septum, where CFAEs are located; these areas need to be ablated to achieve conversion of AF to normal rhythm. It is, thus, very likely that many of our patients may have responded to the pulmonary vein isolation technique. On the other hand, many of our patients were cured by radiofrequency ablations located elsewhere, especially in the septum. These patients may not have benefited from solely the pulmonary vein isolation technique. Our results indicate that our approach is effective and merits further clinical studies to compare it

with the other AF ablation approaches and with the conventional treatment of AF.

Acknowledgments

The authors are indebted to Drs. James Weiss and Peng Cheng for their invaluable comments and critique of the study. We thank Dr. Betty Cohen for her expert editorial assistance.

Reprint requests and correspondence: Dr. Koonlawee Nademanee, Pacific Rim Electrophysiology Research Institute, 575 East Hardy Street, Suite 201, Inglewood, California 90301. E-mail: wee@pacificrimpe.com.

REFERENCES

1. Moe GK, Abildskov JA. Atrial fibrillation as a self-sustaining arrhythmia independent of focal discharge. *Am Heart J* 1959;58:59–70.
2. Allesie MA, Konings K, Kirchhof CJHJ, *et al.* Electrophysiologic mechanisms of perpetuation of atrial fibrillation. *Am J Cardiol* 1996;77:10A–23A.
3. Haissaguerre M, Jais P, Shah DC, *et al.* Spontaneous initiation of atrial fibrillation by ectopic beats originating in the pulmonary veins. *N Engl J Med* 1998;339:659–66.
4. Konings KTS, Kirchhof CJHJ, Smeets JRLM, *et al.* High-density mapping of electrically induced atrial fibrillation in humans. *Circulation* 1994;89:1665–80.
5. Konings KTS, Smeets JLRM, Penn OC, *et al.* Configuration of unipolar atrial electrograms during electrically induced atrial fibrillation in humans. *Circulation* 1997;95:1231–41.
6. Jaïs P, Haïssaguerre M, Shah DC, *et al.* Regional disparities of endocardial atrial activation in paroxysmal atrial fibrillation. *Pacing Clin Electrophysiol* 1996;19:1998–2003.
7. Gerstenfeld EP, Sahakian AV, Swiryn S. Evidence for transient linking of atrial excitation during atrial fibrillation in humans. *Circulation* 1992;86:375–82.
8. Khongphatthanayothin A, Kosar E, Nademanee K. Nonfluoroscopic three-dimensional mapping for arrhythmia ablation: tool or toy? *J Cardiovasc Electrophysiol* 2000;11:239–43.
9. Shpun S, Gepstein L, Hayam G, *et al.* Guidance of radiofrequency endocardial ablation with real-time three-dimensional magnetic navigation system. *Circulation* 1997;96:2016–21.
10. Cox JL, Schuessler RB, Lappas DG, *et al.* An 8 1/2-year clinical experience with surgery for atrial fibrillation. *Ann Surg* 1996;224:267–75.
11. Lewis T. Observation upon flutter and fibrillation. IV. Impure flutter: theory of circus movement. *Heart* 1920;7:293–331.
12. Liu TY, Tai CT, Chen SA. Treatment of atrial fibrillation by catheter ablation of conduction gaps in the crista terminalis and cavo-tricuspid isthmus of the right atrium. *J Cardiovasc Electrophysiol* 2002;13:1044–2046.
13. Tondo C, Scherlag B, Otomo K, *et al.* Critical atrial site for ablation of pacing-induced atrial fibrillation in the normal dog heart. *J Cardiovasc Electrophysiol* 1997;8:1255–65.
14. Quan KJ, Lee JH, Van Hare GF, *et al.* Identification and characterization of atrioventricular parasympathetic innervation in humans. *J Cardiovasc Electrophysiol* 2002;13:735–9.
15. Pappone C, Oreto G, Lamberti F, *et al.* Catheter ablation of paroxysmal atrial fibrillation using a 3D mapping system. *Circulation* 1999;100:1203–8.
16. Chen S-A, Hsieh M-H, Tai C-T, *et al.* Initiation of atrial fibrillation by ectopic beats originating from the pulmonary veins: electrophysiological characteristics, pharmacological responses, and effects of radiofrequency ablation. *Circulation* 1999;100:1879–86.